

# Macroporous Calcium Phosphate Ceramic: A Prospective Study of 106 Cases in Lumbar Spinal Fusion

Rémi Cavagna, M.D.,<sup>1\*</sup> Guy Daculsi, Ph.D.,<sup>2</sup> and Jean-Michel Bouler, Ph.D.,<sup>2</sup>

<sup>1</sup>Clinique du Ter, Unité d'Orthopédie, BP 71, 56275 Ploëmer, France; <sup>2</sup>Centre de Recherche INSERM 99-03 sur les Matériaux d'Intérêt Biologique Faculté de Chirurgie Dentaire, BP 84215, 44042 Nantes Cedex 1, France

\*To whom correspondence should be addressed

Manuscript received: May 7, 1999

Manuscript accepted: June 7, 1999

**ABSTRACT:** Macroporous biphasic calcium phosphate (MBCP, Triosite™) is well known for its safety, absence of allergenicity, and excellent bone-bonding capacity, and it has been widely used as a bone graft substitute in orthopaedic, ENT, and dental surgery. This study investigates the clinical performance of this synthetic porous ceramic in a series of 106 patients, mainly with degenerative spine aetiologies (95/106) and with a minimum follow-up of 2 years. All patients were treated with posterior correction involving the semi-rigid New Orleans™ instrumentation. Spinal fusion was always performed using MBCP granules mixed with autogenous bone chips and bone marrow obtained from the local spine. Fusion of the spine was confirmed for 100 patients, and 6 non-unions were observed (3 resulting from primary spondylolisthesis).

This study shows that MBCP provides suitable results in spinal fusion involving a semi-rigid instrumentation. Because the indication of degenerative spine is not very favorable to fusion, this technique appears to be a good alternative to autografts and could decrease patient morbidity resulting from iliac bone grafting.

**KEYWORDS:** Lumbar spinal fusion, biphasic calcium phosphate, semi-rigid instrumentation.

## I. INTRODUCTION

The use of bone grafting for spinal fusion is well-established.<sup>1</sup> Autogenous bone grafts from the pelvis are considered to be ideal for this procedure, but synthetic bone substitutes may be a good alternative. It is well known that har-

vesting of iliac bone grafts is often accompanied by complications such as increased operative time and blood loss, pain at the donor scar site, and limited quantities of bone stock.<sup>2-4</sup> Banked allograft, when available, does not provide comparable efficiency and is not free from bacterial contamination and viral transmission.<sup>5</sup> Macroporous biphasic calcium phosphate (MBCP) ceramics, which are known for their safety, absence of allergenicity, and excellent bone-bonding capacity, have been widely used as bone graft substitutes in orthopaedic, ENT, and dental surgery.<sup>6-14</sup> To assess these properties in lumbar spinal surgery, we conducted a prospective clinical study associating an MBCP ceramic with semi-rigid spinal instrumentation<sup>15</sup> (MBCP mechanical properties are inadequate for bearing areas).

## II. MATERIALS AND METHODS

### II.1. Macroporous Biphasic Calcium Phosphate (MBCP)

Commercially available MBCP granules (Triosite™, Zimmer, USA) 2-3 mm in diameter were used as a bone-graft substitute. This material consisted of a macroporous ceramic (70% global porosity, macropores 400 to 600 µm in diameter) containing a 60/40 weight mixture of hydroxyapatite and β-tricalcium phosphate.

The MBCP was used at a rate of one 5-g flask for 2 stages, mixed with bone marrow (10 cc per 5 g of material) removed percutaneously from the posterior iliac crest and mixed with bone resection product from spinous processes of vertebrae and or laminae.

### II.2. Graft Technique

The graft technique used was generally articular, based on the technique of Louis,<sup>16</sup> but occasionally posterior or posterolateral. Preparation of the recipient site was always very carefully performed. The articular capsule was resected, and the interspinal line was opened and enlarged with a diamond bur in order to create a 5-mm wide slit in subchondral bone. The bone and marrow substitute was packed into the slit. Posterior and posterolateral grafts were prepared similarly by enlarging the recipient site with the bur.

## II.3. Operating Techniques

### II.3.1. Spinal Instrumentation

All patients were treated with posterior correction using a semi-rigid spinal system<sup>15</sup> (New Orleans™, Zimmer, USA). The modular aspect of the instrumentation (either a single or a partially or totally reinforced 3-mm rod could be used) resulted in 76 semi-rigid, 28 partially rigid, and 2 rigid assemblies.

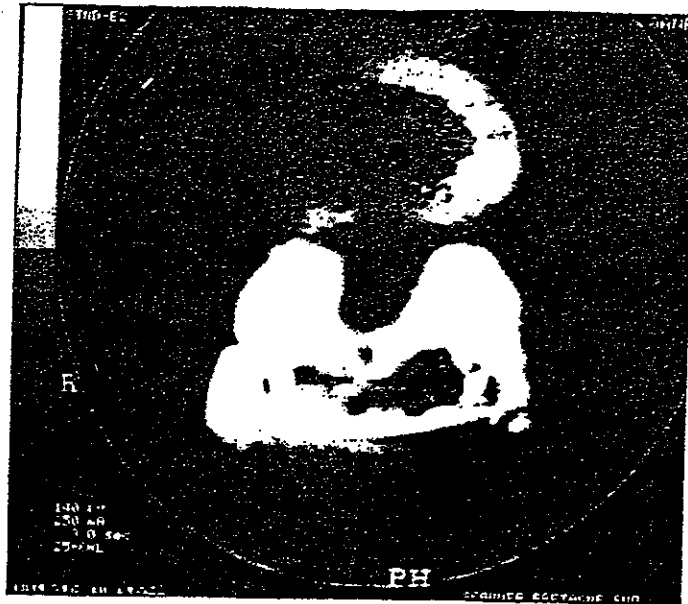
### II.3.2. Postoperative Situation

Patients were on their feet 24 h after the operation without external support and were sent to a rehabilitation centre (CRF Kerpape, Lorient, France) on Day 7. All operated patients received an intraoperative dose of cephalosporin, but none were given postoperative antibiotic therapy. All recovered the blood taken preoperatively, and none received an additional transfusion. Thirty-five patients received major analgesics for 48 h by a PCA pump, whereas the others required only level-2 analgesics. Classic anticoagulant treatment, consisting of low-molecular-weight heparin, was given in all cases.

## II.4. Analysis of Results

All patients were followed up for at least 2 years (26–50 months), and arthrodesis fusion was assessed by X-ray at 3, 6, 12, and 18 months, and then once per year. Each evaluation included frontal, lateral, and three-quarter views. In doubtful cases, a CT scan (2D) was performed. Interpretation of the CT scan was facilitated (see Figure 1) by the graft technique used—generally articular—and by the instrumentation implanted—a 3-mm diameter titanium rod, which limited artifacts). All radiographic documents were examined by two observers, the operator and an independent examiner.

Only one biopsy was performed during ablation of material after fusion for treatment of a callus defect on L1 (see Figure 2). No surgical biopsy had been planned, because the material was to be left in place in order not to complicate the treatment of degenerative spine.



**FIGURE 1.** Example of a CT scan examination of the procedure.

### II.5. Series

The study was performed in 108 patients (57 women, 51 men; mean age 53 years, range 15–79) from 1992 to 1994. Two of the patients died of extra-surgical causes before the minimum follow-up period was reached and were thus excluded from the study, which finally concerned 106 subjects. The series was prospective, non-randomized, and performed by a single operator.

Most of the operated patients (93) presented a degenerative disease (spondylo-

**Table 1.**  
**Aetiologies, Surgical Approaches, and Graft Types Concerned**

Aetiologies	Surgical approaches	Graft types
Primary spondylolisthesis: 8	Laminarthrectomies (8)	Posterolateral (8)
Others:	Laminectomies (50)	Articular (66)
98 (93 degenerative spine/ 5 diverse)	Outside the canal (29)	Posterior (13)
	Laminarthrectomies (19)	Posterolateral (19)

**Table 2.**  
**Total Instrumented Levels**

levels	1	2	3	4	5 and +
number	33	39	12	13	9

listhesis, scoliosis, kyphosis, lumbar stenosis). Eight had primary spondylolisthesis, and 5 had undergone surgery for various pathologies.

### III. RESULTS

#### III.1. Complications

There were no local complications and no inflammatory or infectious effects in this series. Except for the 2 patients who died of extra-surgical causes, there were no general complications.



**FIGURE 2.** Biopsy of the bony callus defect.

**Table 3.**  
**Description of Clinical Failures (Nonunions) Based on the Radiological Results**

Etiologies	Surgical approaches	Graft types
Primary spondylolisthesis: 3	Laminarthrectomies (3)	Posterolateral (3)
Others: 3	Laminectomies (2)	Articular (2)
	Laminarthrectomies (1)	Posterolateral (1)



**FIGURE 3.** Pseudarthrosis: Breakage of the rod at 4 1/2 months in a case of spondylolisthesis.

### III.2. Radiological Results

One hundred arthrodesis were fused, and 6 were non-unions. The latter were unmistakable because of either absence of fusion in the X-ray or breakage of a rod before the 6th postoperative month, indicating mobility of the instrumented segment. These 6 cases related to 3 primary spondylolistheses (see Figure 3), 1 degenerative spondylolisthesis, and 2 diverse aetiologies, described in Table 3.

The chi-square test with Yates correction showed a significant difference in fusion success between primary spondylolisthesis and the other aetiologies ( $\alpha < 0.001$ ). The fusions were also unmistakable because of features on either the X-ray (Figure 4a) or the complementary CT-scan (Figure 4b), associated with the absence of damage to the instrumentation and a favorable clinical course indicative of successful fusion.

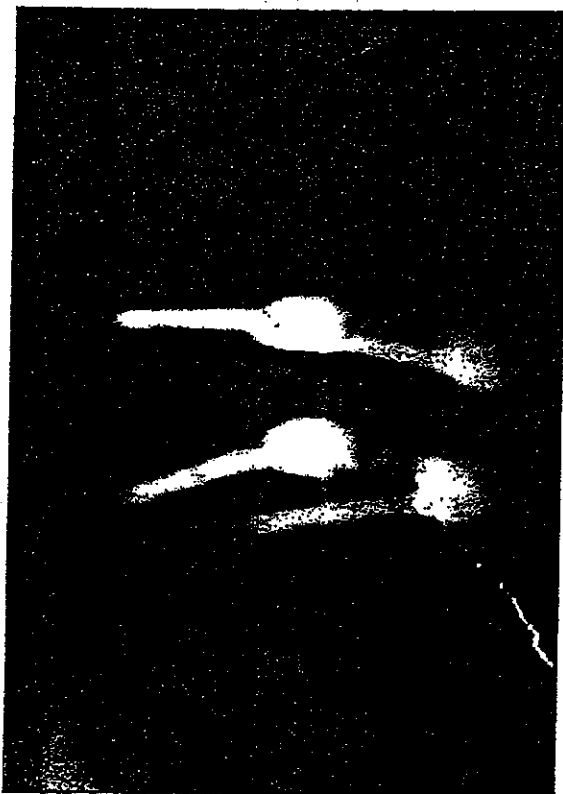
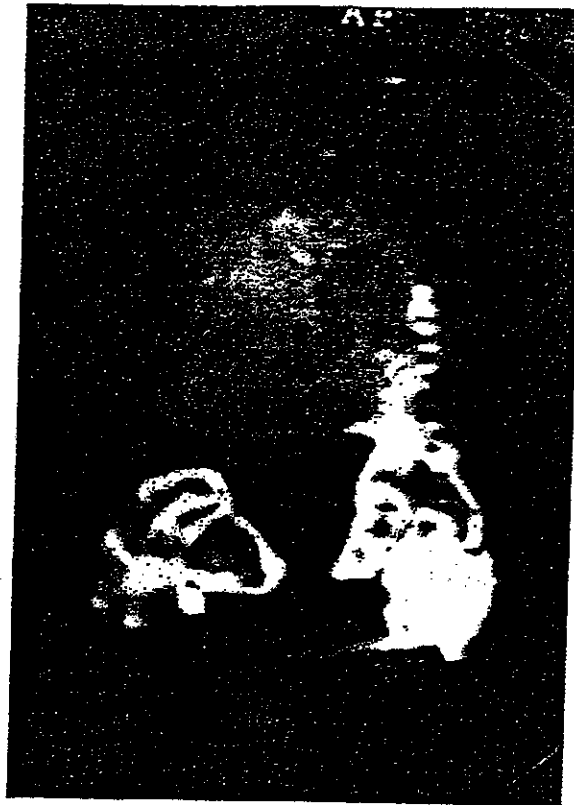

FIGURE 4A. Fusion of the articular graft: X-ray features.



**FIGURE 4B.** Fusion of the articular graft: Confirmation by CT-scan.

#### **IV. DISCUSSION**

The purpose of this prospective study was to analyze the behavior of MBCP as a bone substitute in lumbar arthrodesis. Its efficiency has already been demonstrated in studies of maxillofacial and orthopaedic surgery<sup>6-12</sup> and in correction of severe scoliosis.<sup>13,14</sup>

The originality of this series relates to the nature of the aetiologies, which were essentially degenerative spine disorders (93 out of 106 patients), for which the use of a bone substitute allows a reduction in operating time in subjects (often elderly ones) and avoidance of the potential morbidity involved in obtaining an iliac graft.<sup>17-19</sup> However, local conditions (vascularization, bone quality) are not very favorable to a fusion of the arthrodesis.

The results of the series showed fusion in 100/106 cases, a success rate quite comparable with that of an iliac autograft<sup>16,20-22</sup> and without the inconveniences



noted above. The minimum follow-up of 2 years is largely adequate to confirm the success of bone fusion. The absence of inflammatory or infectious reaction is also indicative of the innocuousness of the bone substitute.

Radiological analysis of the fate of the granules clearly demonstrated their disappearance after the 6th month and the establishment of a homogeneous graft.

Finally, the efficacy of semi-rigid instrumentation has been confirmed in the treatment of degenerative spinal disorders.<sup>15,20</sup> However, it would be of interest to compare these results with a prospective series performed in the same conditions but with conventional rigid instrumentation.

## V. CONCLUSION

This prospective study indicates that MBCP is an efficient substitute for grafting in spinal fusion involving degenerative disorders. The long-term results confirm the biocompatibility of this material in specific bone sites. An MBCP bone substitute provides good perioperative comfort while ensuring a high success rate in the fusion of lumbar arthrodesis.

## REFERENCES

- (1) Golstein, L. A., Treatment of idiopathic scoliosis by Harrington instrumentation and fusion with fresh autogenous iliac bone grafts: Results in 80 patients. *J. Bone Joint Surg. Am.*, 1969, 51:209-222.
- (2) Balderstone, R. A., *Complication in Spinal Surgery*, Philadelphia, PA: Saunders, 1991, 20-22.
- (3) Kahn, B., Superior gluteal artery laceration, a complication of iliac bone surgery. *Clin. Orthop.*, 1979, 140:204-207.
- (4) Lotem, M., Maor, P., and Herimoff, H., Lumbar hernia at an iliac bone graft donor site. *Clin. Orthop.*, 1971, 80:130-132.
- (5) Tomford, W. W., Starkweather, R. J., and Goldman, M. H., A study of the clinical incidence of infection in the use of banked allograft bone. *J. Bone Joint Surg. Am.*, 1981, 63:244-248.
- (6) Daculsi, G., Bagot D'Arc, M., Corlieu, P., and Gersdorff, M., Macroporous biphasic calcium phosphate efficiency in mastoid cavity obliteration. *Ann. Otol. Rhinol. Laryngol.*, 1992, 101:669-674.
- (7) Daculsi, G., Legeros, R. Z., Nery, E., Lynch, K., and Kerebel, B., Transformation of biphasic phosphate ceramics *in vivo*: Ultrastructural and physicochemical characterization. *J. Biomed. Mater. Res.*, 1989, 23:883-894.
- (8) Daculsi, G. and Passuti, N., Effects of macroporosity for osseous substitution of calcium phosphate ceramics. *Biomaterials*, 1990, 11:86-87.
- (9) Nery, E. B., Lee, K. K., and Czajkowski, S., A Veterans Administration cooperative study of biphasic calcium phosphate ceramic in periodontal osseous defects. *J. Periodontol.*, 1990, 61:737-744.
- (10) Nery, E. B., LeGeros, R. Z., Lynch, K. L., and Lee, K., Tissue response to biphasic calcium

- phosphate ceramic with different ratios of HA/β-TCP in periodontal osseous defects, *J. Periodontol.*, 1992, 63(9):729-735.
- (11) Daculsi, G., Passuti, N., Martin, S., Deudon, C., Legeros, R. Z., and Raher, S., Macroporous calcium phosphate ceramic for long bone surgery in humans and dogs—Clinical and histological study, *J. Biomed. Mater. Res.*, 1990, 24:379-396.
  - (12) Gouin, F., Delécrin, J., Passuti, N., Touchais, S., Poirier, P., and Bainvel, J. V., Biphasic macroporous calcium phosphate ceramic bone substitute for bone filling defects: A report of 23 cases, *Rev. Chir. Orthop.*, 1995, 81:59-65.
  - (13) Passuti, N., Daculsi, G., Rogez, J. M., Martin, S., and Bainvel, J. V., Macroporous calcium phosphate ceramic performance in human spine fusion, *Clin. Orthop. Rel. Res.*, 1989, 248:169-176.
  - (14) Ransford, A., Passuti, N., Chopin, D., Morin, C., Michel, E., Garin, C., and Pries, D., Synthetic porous ceramic as bone graft substitute in surgical correction of scoliosis—A prospective randomized study, *J. Bone Joint Surg. Br.*, 1998, 80:13-18.
  - (15) Cavagna, R., New Orleans spinal system in degenerative lumbar disorders (semi-rigid instrumentation), in *Instrumented Fusion of the Degenerative Lumbar Spine: State of the Art, Questions, and Controversies*, Szpalski, M., Gunzburg, R., Spengler, D. M., and Nachemson, A., Eds. Philadelphia: Lipincott-Raven, 1996, 91-104.
  - (16) Louis, R., Lumbo-sacral fusion by internal fixation, *Clin. Orthop.*, 1983, 203:18-33.
  - (17) Kurtz, L. T., Garfin, S. R., and Booth, R. E., Harvesting autogenous iliac bone grafts. A review of complications and techniques, *Spine*, 1989, 1324-1331.
  - (18) Summers, B. and Eisenstein, S., Donor site pain from the ilium. A complication of lumbar spine fusion, *J. Bone Joint Surg. Br.*, 1989, 71:677-680.
  - (19) Younger, E. M. and Chapman, M. W., Morbidity of bone graft donor site, *J. Orthop. Trauma.*, 1989, 3:192-195.
  - (20) Dahl, B., Gerhchen, B., Blyne, P., Klaer, T., and Tondevoid, E., Clinical outcome after spinal fusion with a rigid versus a semi-rigid pedicle screw system, *Eur. Spine J.*, 1997, 6:412-416.
  - (21) Greenough, G., Outcome assessment of lumbar spine fusion, in *Instrumented Fusion of the Degenerative Lumbar Spine: State of the Art, Questions and Controversies*, Szpalski, M., Gunzburg, R., Spengler, D. M., and Nachemson A., Eds. Philadelphia: Lipincott-Raven, 1996, 45-53.
  - (22) Louis, R. and Louis, C., Louis' system for lumbo-sacral fusion, in *Instrumented Fusion of the Degenerative Lumbar Spine: State of the Art, Questions and Controversies*, Szpalski, M., Gunzburg, R., Spengler, D. M., and Nachemson A., Eds. Philadelphia: Lipincott-Raven, 1996:175-184.